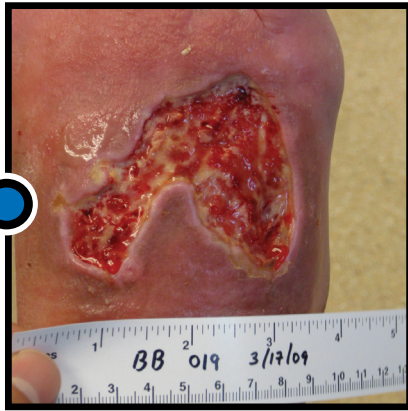
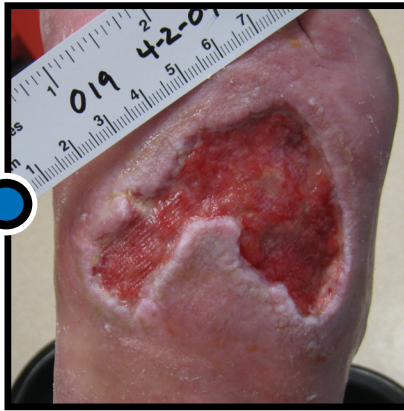

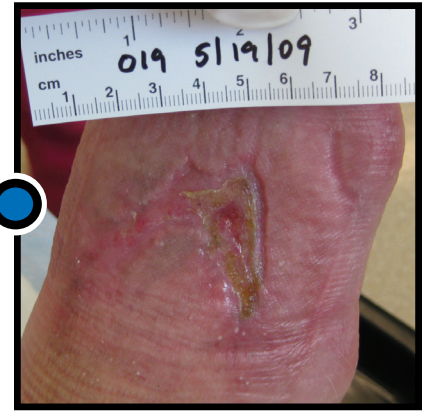# Clinical Case Study: Diabetic Wound



Start of SNaP® Therapy



Week 2



Week 8

- **Patient Information:** 68-year old male
- **Wound History:** Trauma to dorsal foot from door.
- **Dimensions:** Prior to SNaP® Therapy, the wound measured 70 mm X 54 mm, with a depth of 4 mm.
- **Comorbidities:** Diabetes Mellitus, Smoker, Peripheral Vascular Disease, Coronary Artery Disease, COPD, Hypertension, Hyperlipidemia.
- **SNaP® Therapy Treatment:** The patient was treated with SNaP® Therapy for 3 weeks until full granulation of the wound bed was achieved. Then, the SNaP® Therapy was used in conjunction with Apligraf for an additional 5 weeks.
- **Outcome:** Wound closure at approximately 9 weeks post-initiation of SNaP® Therapy.

Spiracur, Spiracur logo, SNaP and SNaP & Design are registered trademarks of Spiracur Inc. The SNaP® Wound Care System is protected by one or more U.S. patents, with other U.S. and certain foreign patents pending. ©2011 Spiracur Inc. All rights reserved.