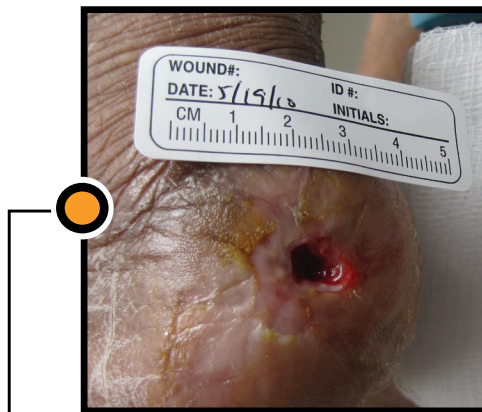
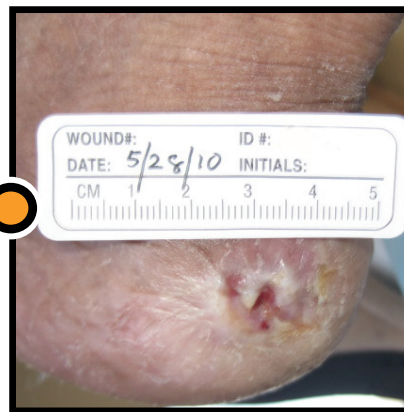

# Clinical Case Study: Heel Pressure Ulcer



Start of SNaP® Therapy



Day 9

- **Patient Information:** 91-year old female
- **Wound History:** Pressure ulcer on the left posterior heel. Wound had been present for 9 months. Previous treatments included Dermagraft, Silvasorb and a heel lift boot.
- **Dimensions:** Prior to SNaP® Therapy, the wound measured 9 mm x 7 mm with a depth of 5 mm.
- **Comorbidities:** Hypertension and peripheral artery disease.
- **SNaP® Therapy Treatment:** Treated with SNaP® Therapy for 9 days for a total of three dressing applications with an average application time of 6.3 minutes.
- **Outcome:** Complete epithelialization and closure achieved one week after SNaP® Therapy discontinued.

Spiracur, Spiracur logo, SNaP and SNaP & Design are registered trademarks of Spiracur Inc. The SNaP® Wound Care System is protected by one or more U.S. patents, with other U.S. and certain foreign patents pending. ©2011 Spiracur Inc. All rights reserved.

L21991 rev. 110714